

Organizing pneumonia after radiation therapy for breast cancer

Erhan Erdoğ an, Figen Başaran Demirkazık, Salih Emri, Pınar Fırat

ABSTRACT

We report a case of organizing pneumonia (OP) that developed after radiation therapy (RT) for breast cancer. A 54-year-old woman presented with malaise and fever within a month after the completion of RT for breast cancer. Chest radiographs and computed tomography (CT) demonstrated consolidation in the left upper lobe consistent with radiation pneumonia. The patient was given 60 mg/day IV cortisone for 15 days after which her complaints and consolidation in the left upper lobe disappeared. The daily dose of her corticosteroid was tapered down to 20 mg/day. Two weeks later, the patient again had fever and malaise. Chest X-ray and CT revealed bilateral pulmonary opacities located outside the irradiated fields, predominantly in the middle and lower lung zones. The patient's laboratory tests were normal except for her erythrocyte sedimentation rate, which was elevated. Bronchial lavage revealed moderate elevation of the total cell number with lymphocyte predominance. Open lung biopsy was performed and histopathological examination demonstrated findings consistent with OP. High dose (60 mg/day) prednisolone treatment resulted in rapid clinical and radiological improvement. When the prednisolone dose was gradually tapered down to 20 mg/day during follow-up, new pulmonary opacities developed in both lungs, as well as the recurrence of the patient's symptoms. Increased dose of prednisolone resulted in the rapid improvement of the clinical symptoms and radiological abnormalities. OP rarely presents after RT for breast and lung cancer. One should always consider OP in the clinical setting of a patient who has a history of RT completed 3-6 months prior to fever, multiple areas of consolidation, and ground glass opacities outside the RT field.

Key words: • bronchiolitis obliterans organizing pneumonia • radiation therapy • breast cancer

Bronchiolitis obliterans organizing pneumonia (BOOP), which has recently been called organizing pneumonia (OP), clinically begins with flu-like symptoms and findings. Later on, fever, dry cough, shortness of breath on exertion, and malaise develop (1). This syndrome, which has no defined exact etiology, can be secondary to many diseases; sometimes it can develop without any etiology (2). It is defined as idiopathic OP or cryptogenic organizing pneumonia (COP) when no underlying cause is present. As a condition clinically similar to lung infection after radiation therapy (RT) characterized by consolidation areas on thorax radiograms, ground glass density and consolidations on CT, OP can be mistaken for radiation pneumonia or lung infection.

Correct diagnosis and treatment of this disease, which most of the time dramatically responds to corticosteroids, both clinically and radiologically, is critical. In this study, a case of OP that developed due to RT is presented.

Case report

A 54-year-old woman who underwent a lumpectomy due to breast cancer 6 months ago had 50 Gy RT to her left breast, and her treatment was completed 1 month ago. She admitted to the hospital with fever, malaise, back and leg pain. The patient did not have complaints of coughing or shortness of breath, but since her fever continued and rhonchi were heard in the middle segment of the left lung, a posterior-anterior chest radiogram and thorax computed tomography (CT) were performed. They revealed consolidation with air bronchogram at the anterior segment of the upper lobe of the left lung; the consolidation was spreading to the lingula and it was consistent with radiation port side (Figure 1). The right lung was normal. The consolidation in the left lung was accepted as radiation pneumonia and 60 mg/day IV steroid treatment was given. The general condition of the patient improved and her fever resolved after steroid treatment. Brucella was identified in blood cultures obtained at that period; thus, the patient was discharged after rifampin and doxycycline were given for brucella.

Steroid dose was slowly tapered down to 20 mg/day since the patient had no complaint 15-20 days after discharge. However, since fever developed again 10 days later, and continued for 1 week, antibiotics for brucella were changed. The patient was re-hospitalized as the fever continued. Thorax CT obtained at that time revealed regression of consolidation in the left upper lobe (Figure 2a), but ground glass densities that were not present in the initial CT were identified (Figure 2b). Additionally, small ground glass densities were seen in basal parts, bilaterally. The sedimentation rate of the patient was high. Bronchoscopy and bronchoalveolar lavage (BAL) were performed. Malign cells, acid-resistant bacilli, or microorganisms were not identified in the lavage sample; but, an increase

From the Departments of Radiology (E.E. ✉ cerhan99@yahoo.com, F.B.D.), Thoracic Diseases (S.E.), and Pathology (P.F.), Hacettepe University School of Medicine, Ankara, Turkey.

Received 6 May 2004; revision requested 14 July 2004; revision received 24 March 2005; accepted 25 March 2005.

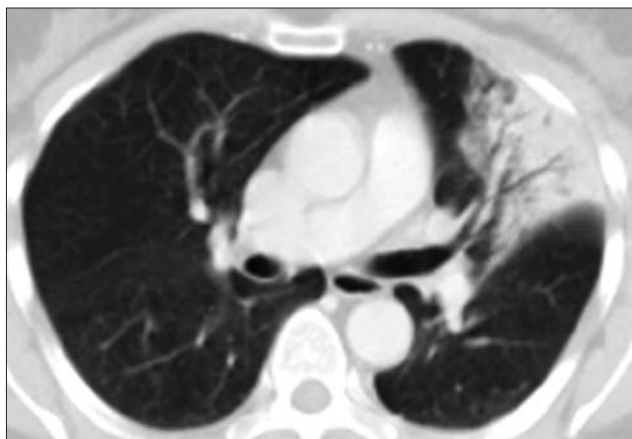


Figure 1. Thorax CT obtained due to fever and malaise in a patient who underwent radiotherapy for breast cancer 1 month ago shows consolidation in the lingular segment of the left upper lobe.

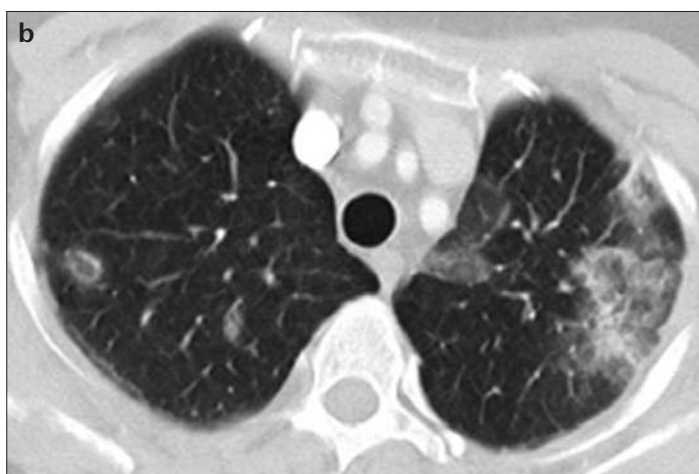
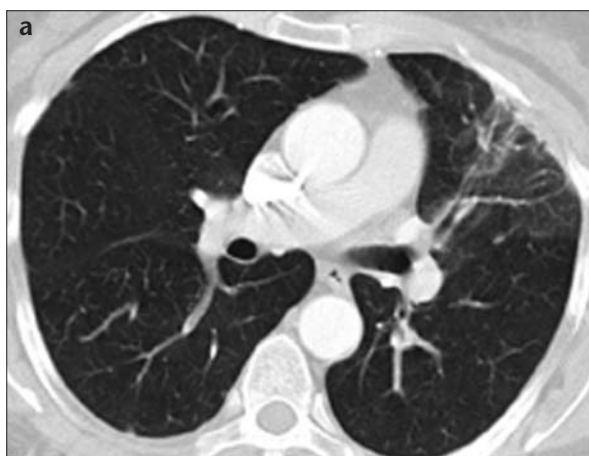

Figure 2. a, b. Disappearance of the lesion in the left lung is seen on follow-up CT 1 month after steroid treatment (a), but new peripherally-located ground glass densities are seen (b).

in total cell number and lymphocyte dominance were seen, and 40 mg/day IV steroid treatment was started.

One-month follow-up thorax CT under steroid treatment revealed progression of ground glass densities in both upper lobes. Additionally, new ground glass densities in both lungs, which

were more prominent in the left lung, were identified (Figure 3 a, b). With the pre-diagnosis of OP, open lung biopsy was performed from the consolidation in the upper lobe of the right lung. In the pathological examination, fibroblastic proliferation with mononuclear cell infiltration forming polypoid structures

within the distal airways and interstitial area were seen, and the diagnosis of OP was confirmed. Since clinical and radiological findings improved with 60 mg/day steroid treatment, the patient was discharged and continuation of steroid treatment was planned.

On follow-up CT obtained 1 month after discharge, it was observed that the ground glass densities had completely disappeared (Figure 4 a, b). On follow-up, steroid dose was tapered down to 20 mg/day, but 15 days later, fever recurred and consolidations appeared on chest radiogram. CT obtained at that time demonstrated ground glass densities in the upper lobe anterior segments adjacent to the pleura in both lungs, in a large area of the lower lobe superior segment of the left lung, and antero-basal segment of the right lung (Figure 5). The steroid dose was increased to 60 mg/day. The complaints of the patient disappeared and no consolidation was identified on chest radiogram. Steroid dose was gradually tapered to 20 mg/day and the patient was followed-up for 2 months without any symptoms. On the last thorax CT, peripheral traction bronchiectasis was seen at the site of the consolidation in the upper lobe of the left lung identified on the initial CT. Additionally, ground glass densities seen on previous CT were nearly completely resolved (Figure 6).

Discussion

OP is an extremely rare disease, but can be easily mistaken for lung infections and other lung diseases, both clinically and radiologically. Histopathologically, the disease is identified by the presence of polypoid granulation tissue within bronchioles, alveolar ductus, and alveoli. Infiltration of airways and interstitium with mononuclear cells and foamy macrophages accompanies granulation tissue within distal airways (3, 4). Patients are usually between 29 and 77 years of age (median: 57) (5). It is seen equally in men and women (6). Clinically, it presents with fever, cough, shortness of breath, and flu-like symptoms. Rarely, hemoptysis and pleuritic chest pain can be seen. Fine crepitations can be heard on auscultation. Laboratory findings are normal, except for increased sedimentation rate and C-reactive protein level (7). Restrictive abnormalities are found in respiratory function tests. Rarely, obstructive findings may accompany.

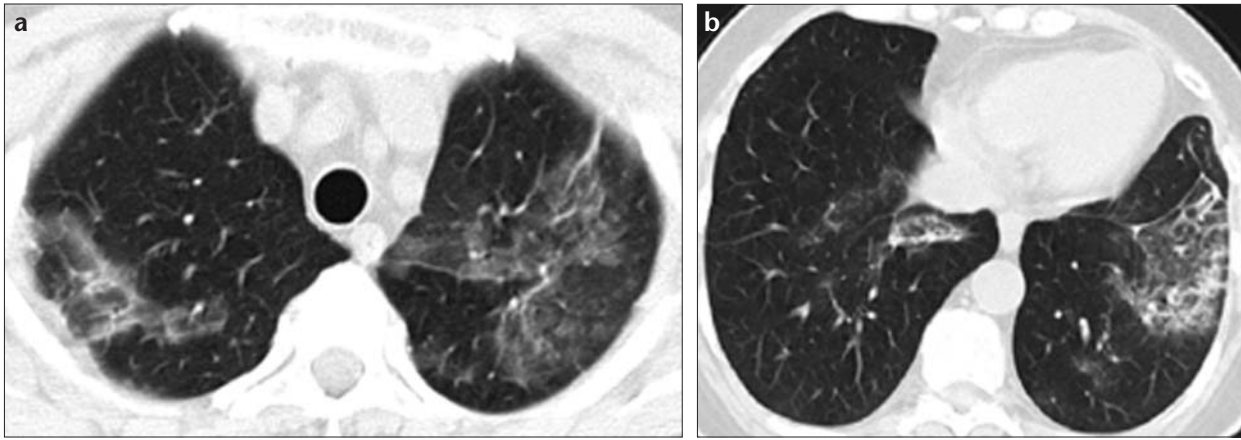


Figure 3. a, b. Twentieth day follow-up CT scan after tapering steroid dose shows ground glass densities that become more widely spread (a) and new ground glass opacities are seen at the lower lobes bilaterally (b).

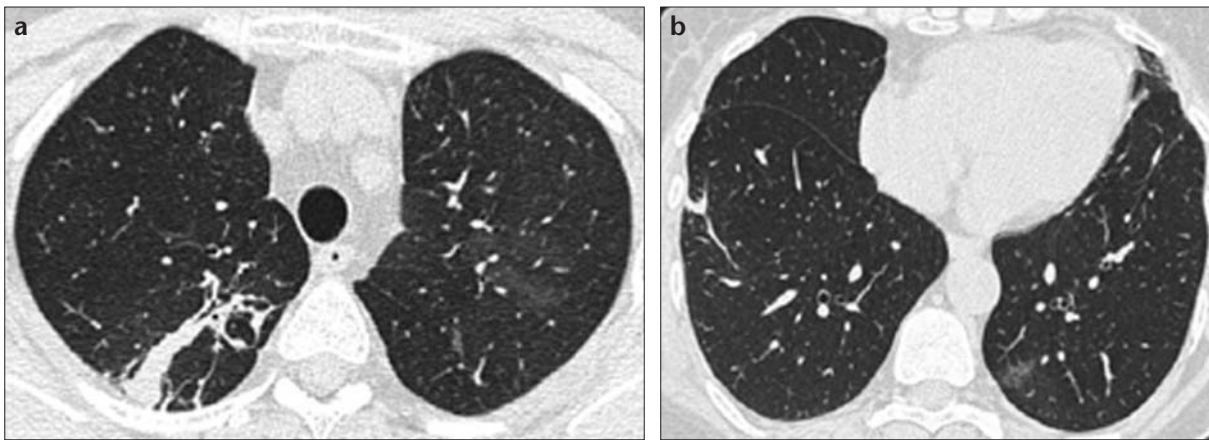


Figure 4. a, b. Disappearance of ground glass densities in upper lobes (a) and lower lobes (b) are seen after increasing the steroid dose.

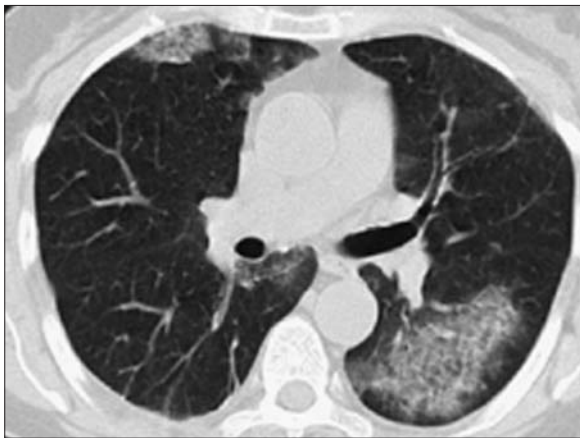

Figure 5. CT scan obtained after tapering the steroid dose shows new ground glass densities in both lungs (right middle lobe and superior segment of lower lobe of left lung).

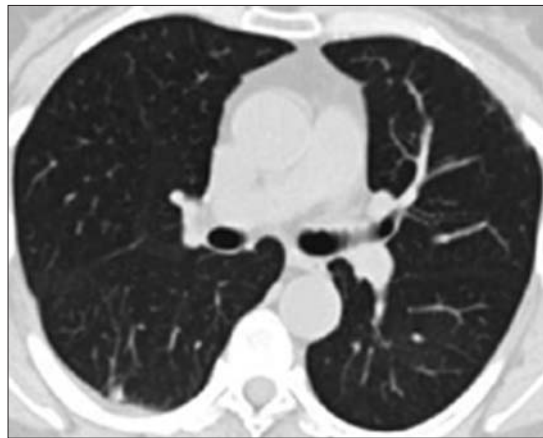


Figure 6. Follow-up CT examination after increasing the steroid dose shows normalizing of both lungs.

BAL is nonspecific and usually various cell types with lymphocyte dominance are commonly seen (8).

The most important radiological finding of COP is bilateral patchy consolidation and ground glass densities. Though consolidation and ground

glass areas are usually observed spreading to whole lobes and segments of lungs, in some series, consolidation areas are found to be located in the mid and basal parts of lungs (9). On CT, consolidation areas are seen more commonly in peribronchovascular and

peripheral parts of lungs. In 10% of patients, opacities are unilateral and focal. Consolidations may change their location, resolve without treatment, and may reappear. On rare occasions, consolidations are seen as nodules with irregular borders, and these nod-

ules may sometimes involve cavitation (10, 11).

Bilateral consolidation areas, fever, cough, and malaise initially suggest lung infection, and then treatment begins. However, if there is no clinical or radiological improvement, peripheral and peribronchovascular localization of consolidation areas and change in their location should alert physicians to the possibility of OP. Histopathological diagnosis is made with examination of material obtained via transbronchial biopsy, percutaneous thick needle biopsy, open lung biopsy, or thoracoscopic biopsy.

Steroids are used in the treatment of OP. Radiological findings and symptoms disappear with steroid treatment in 30%-60% of patients, but disease may recur in 15%. In various series, death due to respiratory failure is reported in 3%-13% of patients (12). Mortality is high in cases of mixed-type OP and in OP secondary to collagen tissue disease.

There are many diseases and conditions that may trigger secondary OP. Among them, several infections, collagen tissue diseases, hematologic malignancies, immune suppressive conditions, cytotoxic, and some antibacterial drugs and RT, as in our case, can be mentioned (2, 6, 12). In several studies, it was found that there is no radiological, clinical, or histopathological difference between secondary and primary OP; however, generally, secondary OP has a worse prognosis (13).

A type of OP that is encountered with increasing frequency is developed secondary to RT in breast cancer patients who had breast-sparing surgery. In a study of 157 patients that received RT after breast-sparing surgery, OP developed in 4 patients (2.5%) (14). The etiopathogenesis of OP secondary to breast cancer RT is not precisely known, but it is proposed that OP is secondary to an autoimmune reaction due to RT. Roberts et al. determined that lymphocytes with an increased ratio of CD4/CD8 were increased in lavage fluid of both lungs in patients who had bilateral breast cancer RT, and they proposed a release of an autoantigen from the lungs with RT (15). Takigawa et al. similarly observed an increase in the number of lymphocytes, neutrophils, and eosinophils with an increased CD4/CD8 ratio in BAL sample of all BOOP cases, and they suggested that lymphocyte in-

filtration in the early period with BOOP development was relevant (14). Nearly all BOOP cases developed due to RT are patients that had RT with tangential radiation following breast-sparing surgery (16). Other than these patients, BOOP was found to develop in a few patients that received RT for small cell lung carcinoma or following mastectomy (17, 18). Why BOOP develops secondary to tangential RT only applied to breasts is not known, but it is known that tangential rays radiate subpleural parts of lungs with lower doses (19).

As in the presented case, OP can be confused with radiation pneumonia. Different from radiation pneumonia, alveolar opacities are seen outside the radiated region in OP and they are migratory. Moreover, consolidations secondary to radiation pneumonia recover with fibrotic changes, but ground glass densities and consolidation areas of OP recover without any sequela. In the literature, in patients with OP secondary to RT, symptoms and radiological findings appear 5-6 months after completing RT (14). Patients generally presented with cough and fever. Bilateral, migratory infiltration areas outside the RT zone are seen. Patients respond rapidly to corticosteroids, both clinically and radiologically. Recurrence of symptoms and radiological findings are nearly always seen after tapering down corticosteroid dose (14). In our case, the presence of peripheral traction bronchiectasis in the upper lobe of the left lung confirmed that the consolidation was due to radiation pneumonia; however, the presence of migratory infiltrations outside the RT zone after regression of radiation pneumonia was consistent with OP. Total clinical and radiological response to steroid treatment and relapse of findings after tapering steroid dose in our case were consistent with other cases in the literature. Differing from the cases in the literature, in ours there was an absence of cough, and instead, the presence of malaise, which was striking.

In conclusion, OP is very easily treated if diagnosed correctly, and should be considered in the differential diagnosis when migratory consolidations outside the radiation field are seen in patients who received RT for breast cancer.

References

1. Oikonomou A, Hansell DM. Organizing pneumonia: the many morphological faces. *Eur Radiol* 2002; 12:1486-1496.

2. Epler GR. Bronchiolitis obliterans organizing pneumonia: definition and clinical features. *Chest* 1992; 102:2-6.
3. Colby TV. Pathologic aspects of bronchiolitis obliterans organizing pneumonia. *Chest* 1992; 102:38-43.
4. American Thoracic Society/European Respiratory Society. International multidisciplinary consensus classification of the idiopathic interstitial pneumonias. *Am J Respir Crit Care Med* 2002; 165:277-304.
5. King TE, Mortenson RL. Cryptogenic organizing pneumonitis: the North American experience. *Chest* 1992; 102:8-13.
6. Alasaly K, Muller N, Ostrow DN, Champion P, FitzGerald JM. Cryptogenic organizing pneumonia: A report of 25 cases and review of the literature. *Medicine (Baltimore)* 1995; 74:210-211.
7. Miyagawa Y, Nagata N, Shigematsu N. Clinicopathological study of migratory lung infiltrates. *Thorax* 1991; 46:233-238.
8. Cordier JF. Cryptogenic organizing pneumonitis. Bronchiolitis obliterans organizing pneumonia. *Clin Chest Med* 1993; 14:677-692.
9. Kim SJ, Lee KS, Ryu YH, et al. Reversed halo sign on high resolution CT of cryptogenic organizing pneumonia: diagnostic implications. *AJR Am J Roentgenol* 2003; 180:1251-1254.
10. Muller NL, Colby TV. Idiopathic interstitial pneumonias: high resolution CT and histologic findings. *Radiographics* 1997; 17:1016-1022.
11. Haddock JAA, Hansell DM. The radiology and terminology of cryptogenic organizing pneumonia. *Br J Radiol* 1992; 65:674-680.
12. Costabel U, Guzman J, Teschler H. Bronchiolitis obliterans with organizing pneumonia: outcome. *Thorax* 1995; 50:59-64.
13. Cohen AJ, King TE, Downey GP. Rapidly progressive bronchiolitis obliterans with organizing pneumonia. *Am J Respir Crit Care Med* 1994; 149:1670-1675.
14. Takigawa N, Segawa Y, Saeki T, et al. Bronchiolitis obliterans organizing pneumonia syndrome in breast conserving therapy for early breast cancer: Radiation-induced lung toxicity. *Int J Radiat Oncol Biol Phys* 2000; 48:751-755.
15. Roberts CM, Foulcher E, Zaunders JJ, et al. Radiation pneumonitis: A possible lymphocyte-mediated hypersensitivity reaction. *Ann Intern Med* 1993; 118:696-700.
16. Nambu A, Araki T, Ozawa K, et al. Bronchiolitis obliterans organizing pneumonia after tangential beam irradiation to the breast: Discrimination from radiation pneumonitis. *Radiat Med* 2002; 20:151-154.
17. Van Haecke P, Vansteenkiste J, Paridaens R, et al. Chronic lymphocytic alveolitis with migrating pulmonary infiltrates after localized chest wall irradiation. *Acta Clin Belg* 1988; 53:39-43.
18. Kaufmann J, Komorowski R. Bronchiolitis obliterans: A new clinical-pathologic complication of irradiation pneumonitis. *Chest* 1990; 97:1243-1244.
19. Crestani B, Valeyre D, Roden S, et al. Bronchiolitis obliterans organizing pneumonia syndrome primed by radiation therapy to the breast. *Am J Respir Crit Care Med* 1998; 158:1929-1935.